

Negative-Pressure Wound Therapy (NPWT) Compared to Conventional Dressing in the Management of Acute Injuries of Extremities

TAREK ABULEZZ, M.D.

The Department of General Surgery, Plastic Surgery Unit, Faculty of Medicine, Sohag University, Sohag, Egypt

ABSTRACT

Background: Acute injury to extremities is a common surgical challenge. Road Traffic Accidents (RTA) are the most common etiology and are usually associated with soft tissue injuries and fracture patterns. Other injuries include gunshots, firework and burns. Negative-Pressure Wound Therapy (NPWT), also known as Vacuum-Assisted Closure (VAC), has revolutionized the wound care protocols. The use of NPWT has become quite common in chronic wounds, but only was reported in very few literatures as an immediate management in acute injuries.

Objectives: To evaluate early use of NPWT compared to conventional dressings in the management of acute injuries in upper and lower limbs with tissue loss and/or open fracture.

Methods: The study included 47 consecutive patients divided into 2 groups: The first group included patients who received NPWT after initial surgical debridement and fracture fixation if required. This group included 27 patients with age ranged from 3 to 73 years with average 38 years. The second group received conventional wound dressing and included 20 patients whose ages ranged from 15 to 46 with an average of 30.5 years.

Results: NPWT reduced wound size of 1.7 times more compared to conventional dressings. It also reduced the average healing time to 18.5 days in the NPWT group compared to 28 days in conventional dressing group.

Conclusion: NPWT is a safe, simple and cost-effective technique in the management of acute limb injuries.

Key Words: NPWT – VAC – Vacuum – RTA – Acute extremities injury – Negative-pressure – Trauma.

INTRODUCTION

Road Traffic Accidents (RTA) constitute a major part of the casualties and traumatic injuries. The crush component in Road Traffic Accidents (RTA) increases the severity of soft-tissue devi-

talization and the subsequent septic complications specially if Grade III on Gustilo classification [1]. It is difficult to form healthy granulation tissue by simple wet dressing, when a tendon, bone, or implant is exposed [2]. The goals and mechanisms of action of the NPWT are multimodal and were mentioned in many review articles before [3,4].

NPWT or Vacuum-Assisted Closure (VAC) therapy consists of three components: A negative pressure generating unit with a disposable canister, a pad with evacuation tube, and a reticulated, open cell sterile polyurethane or a dense open-pore polyvinyl alcohol foam dressing cut to fit the wound (KCI, 2006), allowing subatmospheric pressure applied to the sponge to be distributed equally throughout the sponge. NPWT usually applies a –70 to –150mmHg vacuum as a continuous mode [5]. Many innovations and modifications have been added to the NPWT over time. Different mode of NPWT which is called Intermittent Pressure Therapy (IPT) results in faster wound healing, but it is not often used clinically as the sudden changes in pressure cause the foam to expand and contract repeatedly over the granulation tissue, causing pain. Variable Pressure Therapy (VPT) has been also introduced to provide a smooth transition between two different pressure environments with more wound contraction and granulation tissue formation was found following IPT and VPT than continuous NPWT [6].

Reeves et al., did a study combining the use of VAC with Acticoat™, showed a significant decrease in wound infection even without long use of antibiotics [7]. There is also GranuFoam®

which is an antimicrobial Silver foam dressing specifically engineered for use with V.A.C.®, which provides the full benefits of V.A.C.® while offering antimicrobial protection with bacterial concentration decreased by greater than a 4-log reduction and percent bacterial reduction of at least 99.9% [8].

There have been several novel approaches to increase the efficiency of NPWT. As it can be also used with orthobiologics for dermal replacement to maintain contact between the biological layer and the wound, reducing micro-motion [9]. Cunningham combined the use of Acellular Dermal Regeneration Template (ADRT) with NPWT followed by STSG after Mohs surgery [10]. Although it was a simple combination Cunningham did, it may lead to an outstanding improvement in the reconstruction on a broader scale. ADRT was used alone in reconstruction of digits with exposed tendon or bone followed by FTSG [11]. But up till now there are no studies of combined use of ADRT with NPWT in reconstruction of extremities trauma followed by STSG. Furthermore, in an attempt to lower the cost of the expensive VAC technology, wall-suction systems have been tried [12].

PATIENTS AND METHODS

The study was conducted on patients who had acute limb injuries who were admitted to Aseer Central Hospital, Abha, KSA, in the period between Jan. 2011 and March 2013. All patients who were referred to the emergency department had resuscitation measures to stabilize the general conditions then surgical debridement and fixation of fractures-if existed-were done. Systemic antibiotics prophylaxis was given. Correction of anemia and high protein diet were considered to both groups.

Study design:

The study included 47 consecutive patients who were randomly assigned into two groups: In the 1st arm of the study, 27 patients received NPWT (22 were males and 5 females). Twenty cases of them were lower extremity injury, 4 cases were upper extremity injury and 3 in the back of the trunk and the age of the patients ranged from 3 to 73 years with an average age of 38 years. The concept of NPWT, its benefits and restrictions and possible complications were discussed with the 27 patients or their families and an informed written consent was been obtained from each patient or his guardian before starting the treatment. The 2nd arm of the study included 20 patients (18 were

males and 2 females), 14 cases were lower limb injury, 5 of upper limb injury and one in the buttocks (Table 1), with the age ranging from 15 to 56 with an average of 30.5 years.

Inclusion criteria: Patients who had acute traumatic injury extremities, with or without tendon or bone exposure Gustilo grade IIIa and grade IIIb.

Exclusion criteria:

- 1- Patients who had unstable general conditions with Glasgow Coma Scale less than 10.
- 2- Gustilo grade IIIc victims.
- 3- Severe limb threatening injuries according to Lower Extremity Assessment Project [13].
- 4- Patients with blood dyscrasia or known bleeding tendencies.

Techniques used:

NPWT was applied to the 1st group from day 0 in continuous mode, after the initial debridement and thorough wound irrigation. The negative pressure is adjusted to -75mmHg in the first 24 hour, and then gradually raised to -120mmHg with 10 mmHg increment per day. The wound dressing is changed every 72h [14].

The 2nd group had conventional wound dressings done by povidine iodine ± hydrogen peroxide, then application of antibiotic impregnated gauze, with changing of dressing every other day.

Tracing of wound dimensions was done every week using a ruler to measure the length, width and the depth of the wound. Wounds had been treated until the granulation tissue appeared to prepare the bed for STSG/FTSG or local/free flap.

RESULTS

In NPWT, the wound closed with 2ry intention in 9 cases 33% (n=9). 1 case 10% (n=1) needed local flap, and in the remaining 17 patients 63% (n=17) the wound was closed with a STSG. While in the conventional dressing group, number of wounds closed with 2ry intention was 20% (n=4), STSG was used in 65% (n=13), FTSG in 5% (n=1) and in 10% (n=2) required local flap. In the group of NPWT, most of patients required STSG 63% (n=17), while 33.3% (n=9) closed spontaneously with 2ry intention and only 1 case (n=1) 3.7% needed local flap. On the other hand, the conventional dressing group, wounds closed spontaneously with 2ry intention were 20% (n=4), while STSG

was used in 65% (n=13), FTSG in 5% (n=1) and in 10% (n=2) needed local flap.

The time for granulation tissue in NPWT group was 9 to 28d with an average of 18.5 days. While in the conventional dressing group, it was 11 to 45d with an average of 28 days. NPWT reduced wound size by 77.8%, while the reduction in conventional dressing was 46.1%. It means that NPWT reduced wound size of 1.7 times more compared to conventional dressings.

Follow-up was done over 3 months: On weekly bases for the 1st month, twice a month in the 2nd month and 3rd month. There was no loss of long term follow-up except for 1 subject due to relocation. There were neither complications of retained sponge nor device malfunction. Only 4 patients had scar contracture in grafted area with subsequent release. 3 patients reported itching in the skin under NPWT system.

Case examples:

Case number 1: Thirty-three years old female patient sustained an RTA and was presented with an open fracture femur with exposed plate. At

admission, the wound measured 15cm long, 8.5cm wide and 5cm in depth. After 7 VAC dressing cycles, the wound dimensions were 9cm length, 5cm width and 2.5cm in depth. There was good granulation tissue and the wound was ready for split-thickness skin grafting Fig. (1).

Case number 2: Twenty-seven years old male patient who had firearm shot left tibia and was presented with an open fracture tibia. External fixator was used to stabilize the tibia and VAC dressing was applied to the wound after initial debridement. The wound was 9cm long, 6cm wide at application of the VAC. After 4 VAC dressing cycles (12 days) the wound was 5cm long and 3.5cm wide with good granulating surface. Split-thickness skin graft was applied Fig. (2).

Case number 3: Forty-six years old male patient with MCA resulting in a deep wound measuring 17 X 9cm in diameters in the posterolateral aspect of the left thigh with exposure of muscle and tendons, NPWT was applied. After 4 cycles the diameters were 9 X 4cm and after another 5 cycle the wound was partially healed with a remaining linear scar of about 9cm Fig. (3).

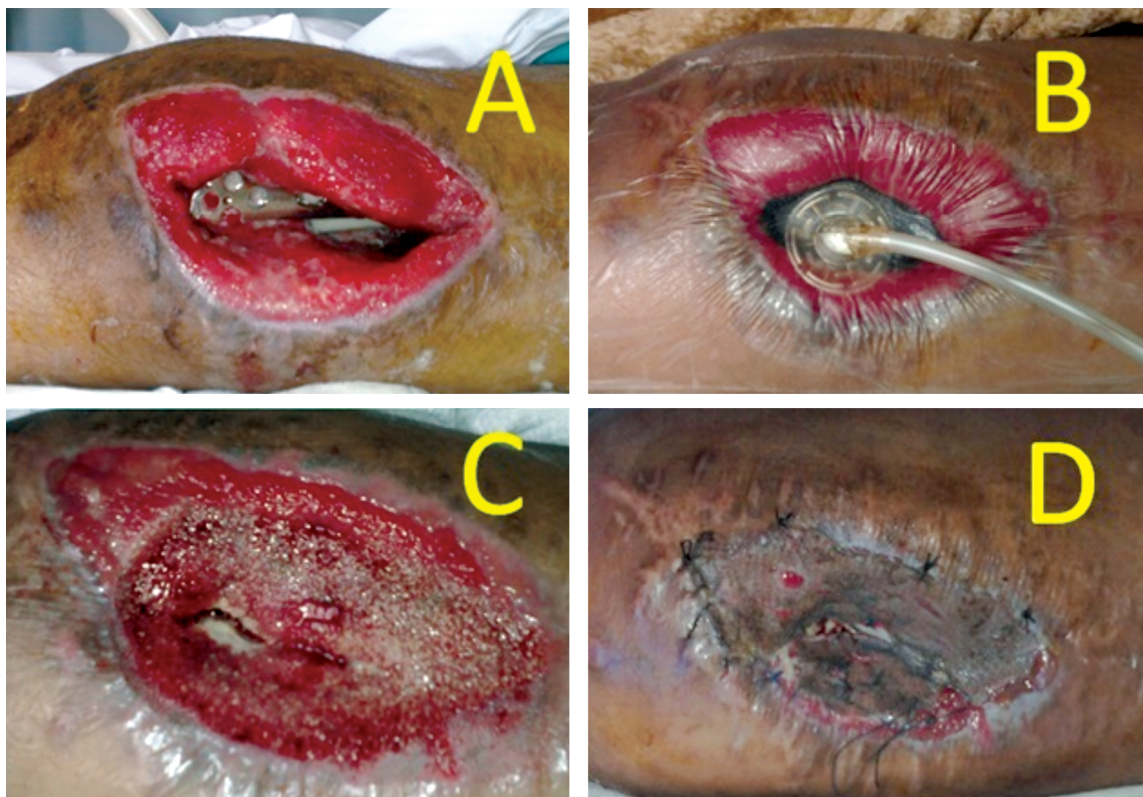


Fig. (1): Example of a successful closure with NPWT in right thigh of a 33-years old female patient; (A) Posttraumatic open fracture femur caused by RTA with exposed plate, (B) VAC dressing was applied, (C) Plate is covered and granulation tissue ready for grafting, (D) The wound grafted with STSG.

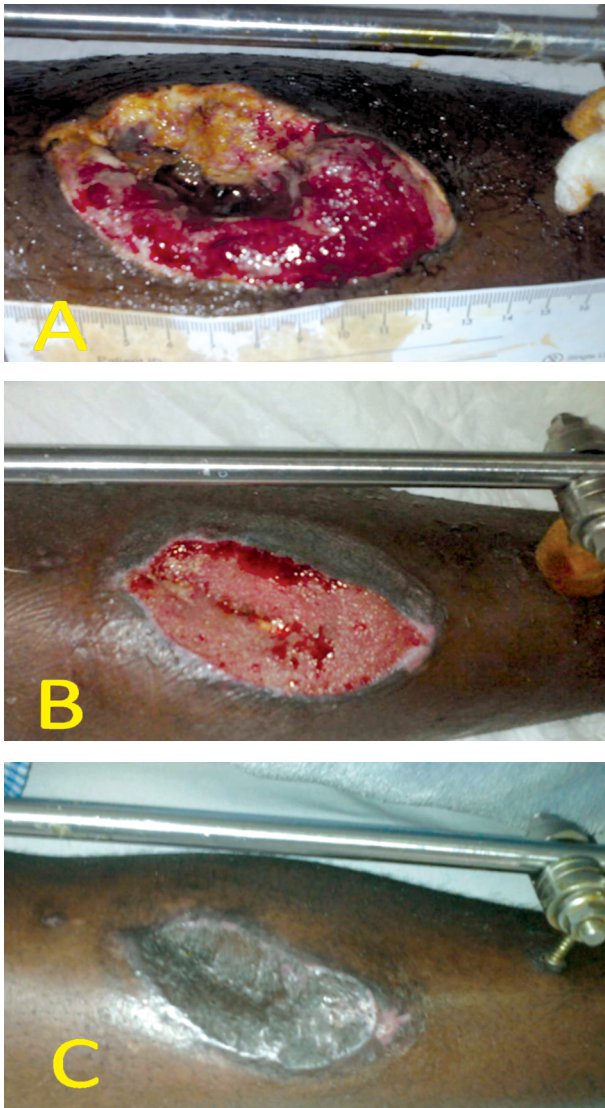


Fig. (2): Gunshot to the leg with open fracture tibia; (A) Debridement was done and VAC applied, (B) After 4 cycles (12 days) of VAC therapy, (C) Graft was applied.

DISCUSSION

Use of NPWT has changed the merits of the classic reconstructive ladder [15]. Immediate use of NPWT can significantly reduce hospital stay [16] and subsequently nosocomial infections and depressive psychological impact of that vicious cycle of being ill. The conventional wound dressings adhere to dead tissue. When the gauze is removed, it also removes viable and nonviable tissue and may damage the granulation tissue with its new epithelial cells [17]. Our concept of early use of NPWT in acute limbs trauma is to shorten duration of treatment which is the main advantage of it. This will allow early ambulation and early

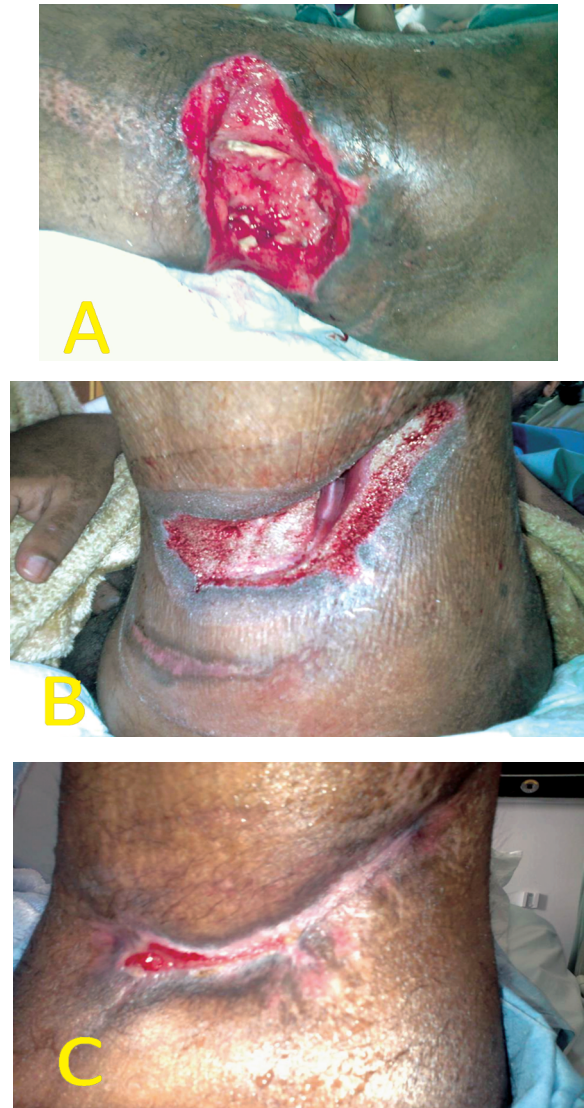

Fig. (3): (A) Post traumatic wound in the middle of the posterolateral aspect of the left thigh with measuring approximately 17 X 9cm. (B) After 4 cycles of NPWT, the wound is about 10 X 4cm. (C) After another 5 cycles the wound is almost a 9-cm long linear.

restoration of limb function. NPWT also decreases the complications such as disuse atrophy. With the shortened duration of treatment and early mobilization of the patient, NPWT limits the need for postoperative physiotherapy.

The outcome of our result was compared to a study done by Bollero et al., where they reported that after the use of NPWT. 66% of cases needed STSG, local flaps 13% and direct suture of 8% [18].

Blume et al., found 80% reduction in the risk of deep tissue infection between NPWT and conventional dressing treatment after adjustment for multivariate analysis [19]. In our study, the time

for granulation tissue in NPWT group was 9 to 28 with an average of 18.5 days, while it was 11 to 45d with an average of 28 days in the conventional dressing group.

Blume et al., found that wound size reduction of chronic ulcer with NPWT was 43.2% compared to conventional dressing 28.9% [19]. We got higher percentage for NPWT which was 77.8%, while conventional dressing was 46.1%; due to the early impact of NPWT in decreasing bacterial load. It means that NPWT made wound size reduction of 1.7 times more compared to conventional dressings.

However, NPWT does not replace the well-established surgical procedures such as careful surgical wound debridement, controlling wound infection and improving blood circulation when compromised. When significant wound infection or gangrene in the wound is present, NPWT is better postponed until wound infection is controlled and necrotic tissues are debrided. NPWT should be used with caution when there is a risk of bleeding from the wound [12].

Limitations:

In our study, we didn't add Acticoat™ or GranuFoam® in combination with NPWT. We couldn't use Variable Pressure Therapy (VPT) as a different modality of NPWT.

Conclusion:

Despite awareness of all benefits of NPWT, it is still used after failure of the conventional management. Our study shows that early use of NPWT in acute extremity injuries is superior to standardized dressing protocols in achieving the best outcome of healing and least percentage of infection.

Conflict of interest and funding:

The authors have neither financial nor intellectual conflict of interest to declare in relation to the content of this article.

Fundings: None.

Acknowledgements: The author expresses his sincere gratitude to Dr. Habib Kant: Senior Resident Plastic Surgery Dept. & Burn Unit, Aseer Central Hospital, Abha, Kingdom of Saudi Arabia, who helped a lot in dressing and following the patients. I also express my deep thanks to Dr. Nancy Al-Sebaiy, Ph.D. candidate in Plastic and Reconstructive Surgery Department at Cairo University and a fellow at Rhön-Klinikum, Bad Neustadt, Bavaria, Germany, for her invaluable contribution in writing and editing the manuscript.

REFERENCES

- 1- Gustilo R. and Anderson J.: Prevention of infection in the treatment of one thousand and twenty-five open fractures of long bones: Retrospective and prospective analyses. *The Journal of Bone & Joint Surgery*, 58 (4): p. 453-8, 1976.
- 2- DeFranzo A.J., Argenta L.C., Marks M.W., et al.: The use of vacuum-assisted closure therapy for the treatment of lower-extremity wounds with exposed bone. *Plast. Reconstr. Surg.*, 108 (5): p. 1184-91, 2001.
- 3- Falanga V.: Growth factors and chronic wounds: The need to understand the microenvironment. *J. Dermatol.*, 19 (11): p. 667-72, 1992.
- 4- Lancerotto L., Bayer L.R. and Orgill D.P.: Mechanisms of action of microdeformational wound therapy. *Semin. Cell. Dev. Biol.*, 23 (9): p. 987-92, 2012.
- 5- Saxena V., Hwang C.W., Huang S., Eichbaum Q., Ingber D. and Orgill D.P.: Vacuum-assisted closure: Microdeformations of wounds and cell proliferation. *Plast. Reconstr. Surg.*, 114 (5): p. 1086-96; discussion 1097-8, 2004.
- 6- Malmström M., Gustafsson L., Lindstedt S., Gesslein B., and Ingemansson R.: The effects of variable, intermittent, and continuous negative pressure wound therapy, using foam or gauze, on wound contraction, granulation tissue formation, and ingrowth into the wound filler. *Eplasty*, 12: p. e5, 2012.
- 7- Reeves I., Plourde M., Authier S. and Doddridge C.: [Combined effect of Acticoat and VAC on wound healing]. *Perspect Infirm*, 2 (5): p. 10-5, 2005.
- 8- KCI S.A. and TX V.A.C.: GranuFoam Silver® Dressings The Only Antimicrobial Silver Foam Dressing Specifically Engineered for Use with V.A.C.® Therapy, 2012.
- 9- Ramanujam C.L., Stapleton J.J. and Zgonis T.: Negative-pressure wound therapy in the management of diabetic Charcot foot and ankle wounds. *Diabet Foot Ankle*, 4, 2013.
- 10- Cunningham T. and Marks M.: Vacuum-assisted closure device and skin substitutes for complex Mohs defects. *Dermatol. Surg.*, 40 Suppl 9: p. S120-6, 2014.
- 11- Taras J.S., Sapienza A., Roach J.B. and Taras J.P.: Acellular dermal regeneration template for soft tissue reconstruction of the digits. *J. Hand. Surg. Am.*, 35 (3): p. 415-21, 2010.
- 12- Vikatmaa P., Juutilainen V., Kuukasjärvi P. and Malmivaara A.: Negative pressure wound therapy: A systematic review on effectiveness and safety. *European journal of vascular and endovascular surgery: The official journal of the European Society for Vascular Surgery*, 36 (4): p. 438-48, 2008.
- 13- MacKenzie E.J. and Bosse M.J.: Factors influencing outcome following limb-threatening lower limb trauma: Lessons learned from the Lower Extremity Assessment Project (LEAP). *J. Am. Acad. Orthop. Surg.*, 14 (10 Spec No.): p. S205-10, 2006.
- 14- E., K., L., B., C., L., et al.: Evidence-based recommendations for the use of Negative Pressure Wound Therapy in traumatic wounds and reconstructive surgery: Steps towards an international consensus. *Injury*, 42 (Suppl 1): p. S1-12, 2011.

- 15- Ullmann Y., Fodor L., Ramon Y., Soudry M. and Lerner A.: The revised "reconstructive ladder" and its applications for high-energy injuries to the extremities. *Ann. Plast. Surg.*, 56 (4): p. 401-5, 2006.
- 16- Dedmond B.T., Kortesis B., Pungert K., et al.: Subatmospheric pressure dressings in the temporary treatment of soft tissue injuries associated with type III open tibial shaft fractures in children. *J. Pediatr. Orthop.*, 26 (6): p. 728-32, 2006.
- 17- Alvarez O.M., Mertz P.M. and Eaglstein W.H.: The effect of occlusive dressings on collagen synthesis and re-epithelialization in superficial wounds. *J. Surg. Res.*, 35 (2): p. 142-8, 1983.
- 18- Bollero D., Carnino R., Risso D., Gangemi E.N. and Stella M.: Acute complex traumas of the lower limbs: A modern reconstructive approach with negative pressure therapy. *Wound Repair Regen*, 15 (4): p. 589-94, 2007.
- 19- Blume P.A., Walters J., Payne W., Ayala J. and Lantis J.: Comparison of negative pressure wound therapy using vacuum-assisted closure with advanced moist wound therapy in the treatment of diabetic foot ulcers: A multicenter randomized controlled trial. *Diabetes Care*, 31 (4): p. 631-6, 2008.